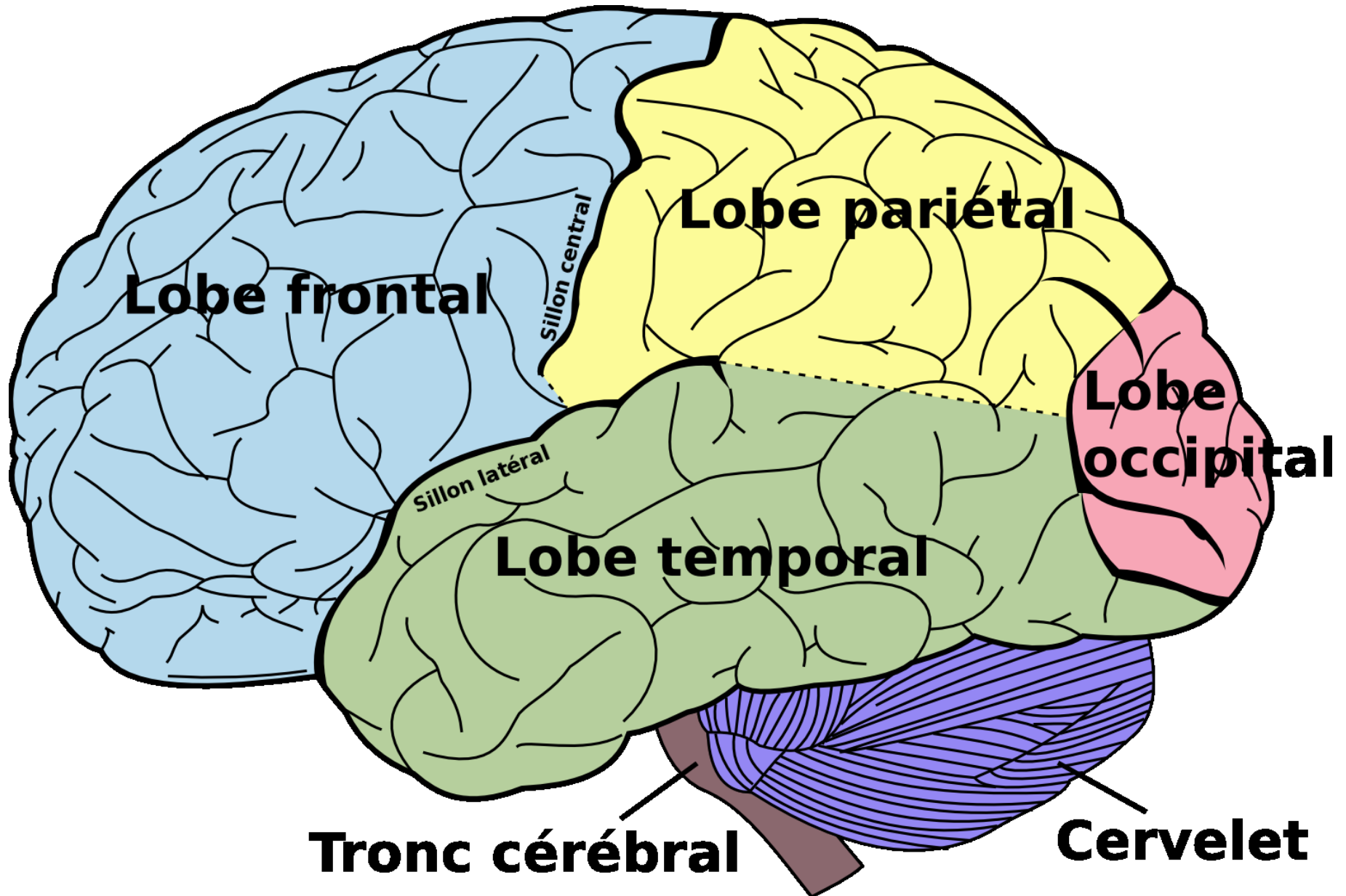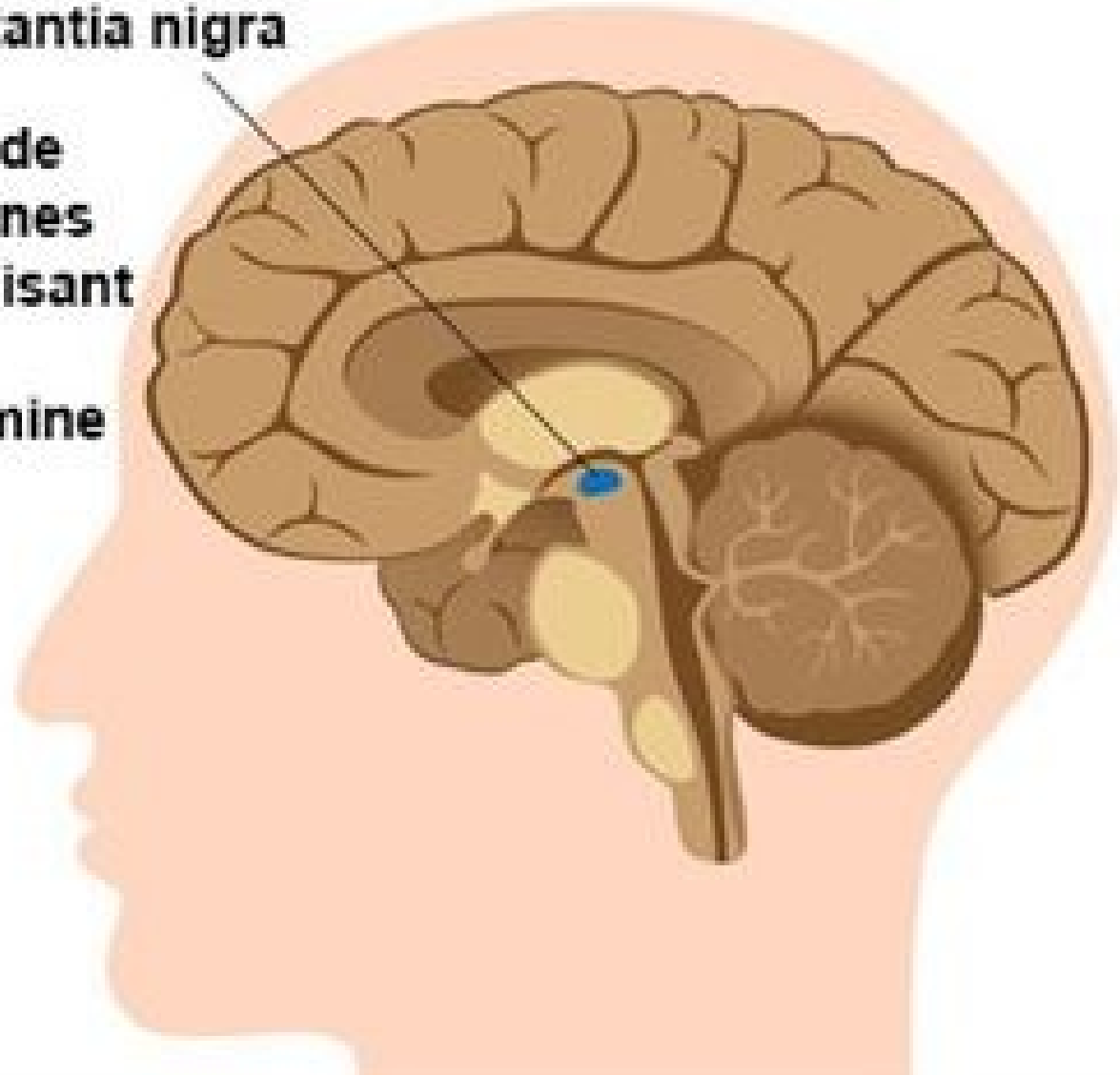


Maladie de Parkinson

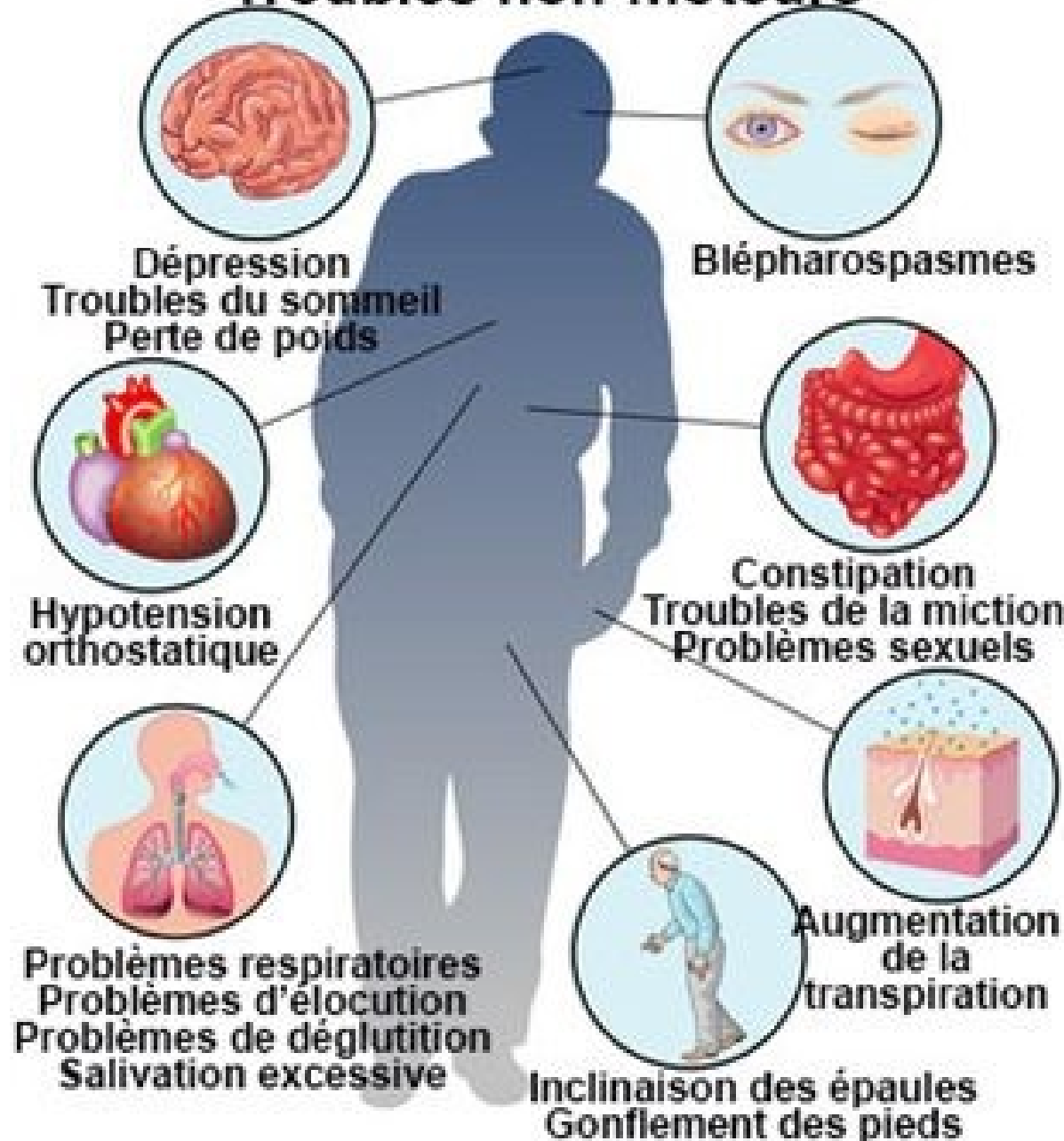
Substantia nigra

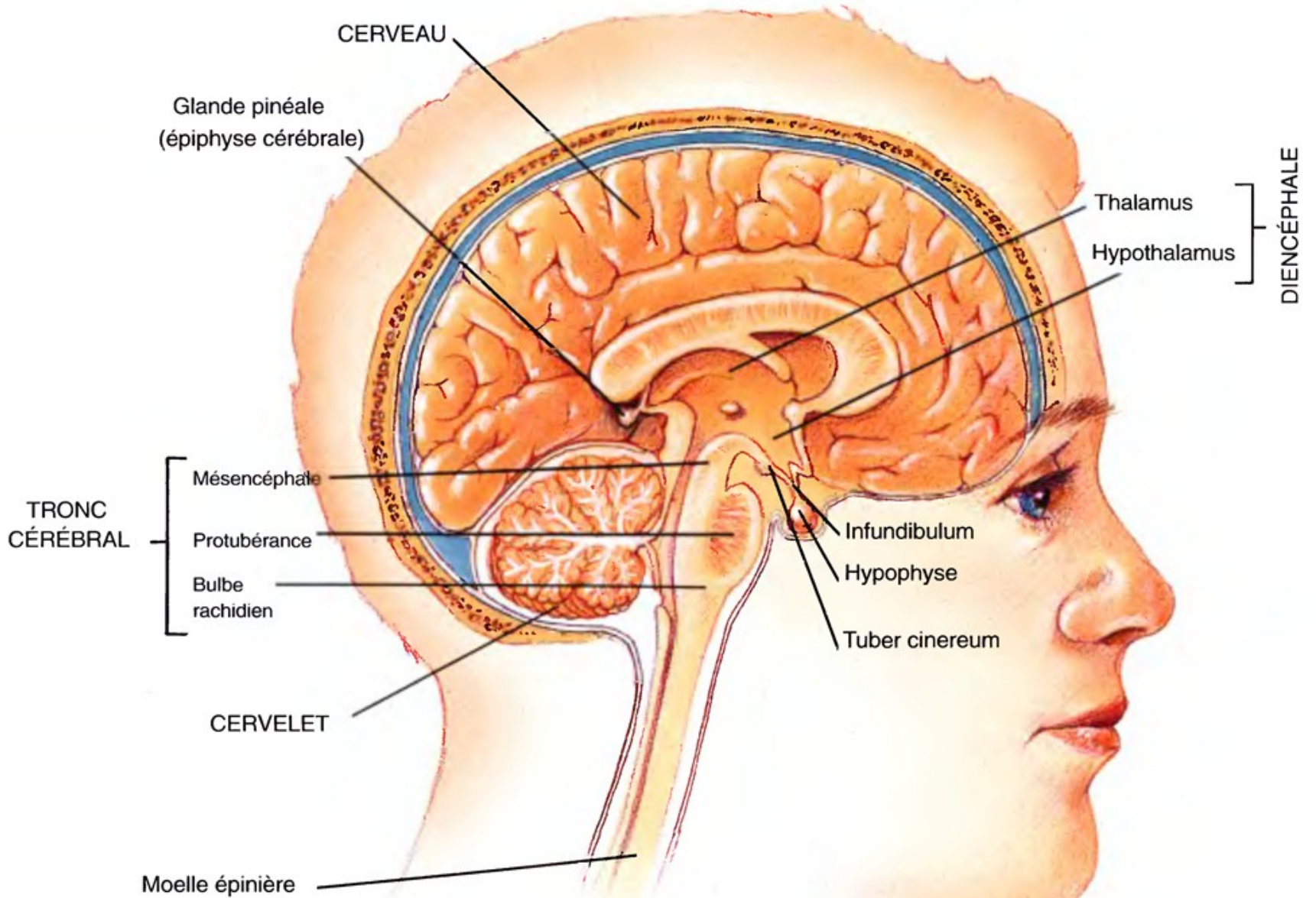
Perte de
neurones
produisant
la
dopamine



Maladie de Parkinson

Troubles non-moteurs

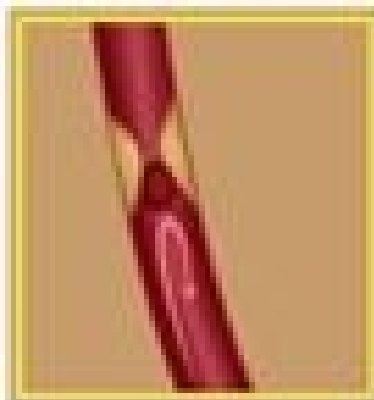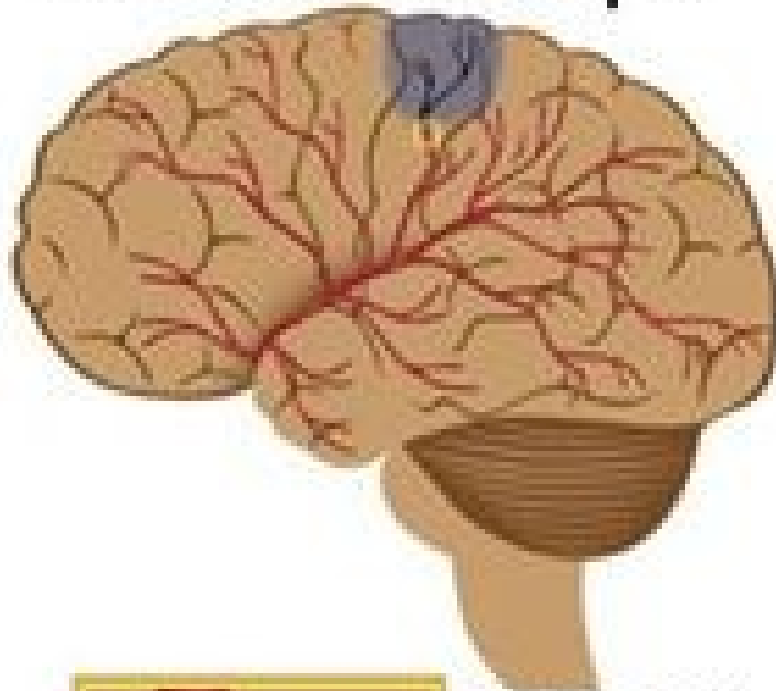




Coupe sagittale de la région médiale de l'encéphale

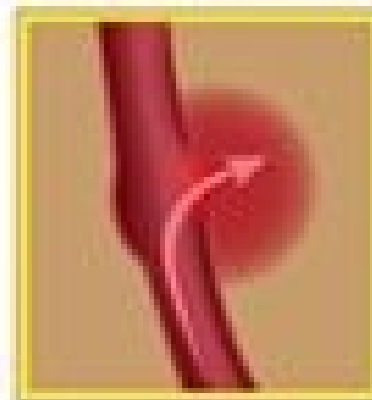
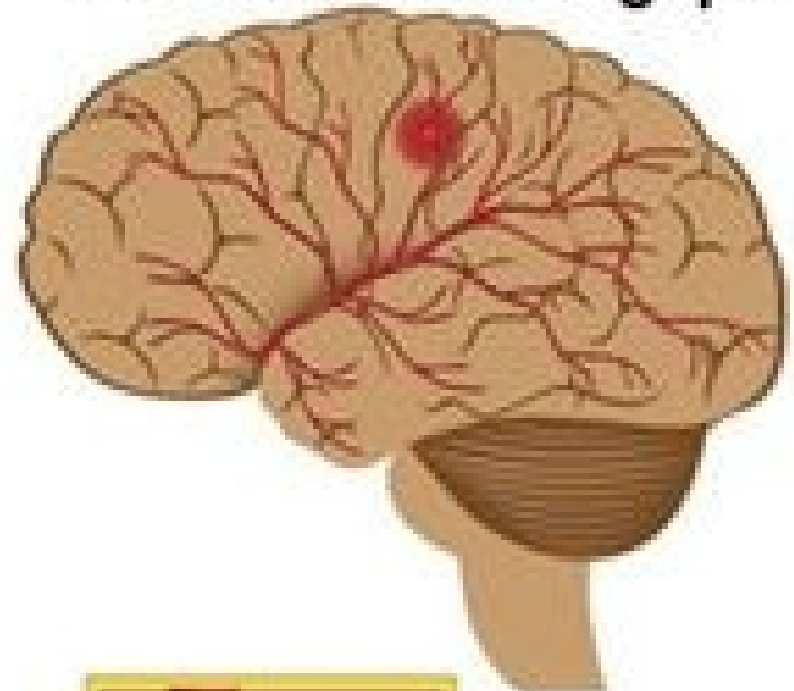
AVC: accident vasculaire cérébral

Accident ischémique



Vaisseaux bouchés, interruption du flux sanguin dans la zone affectée

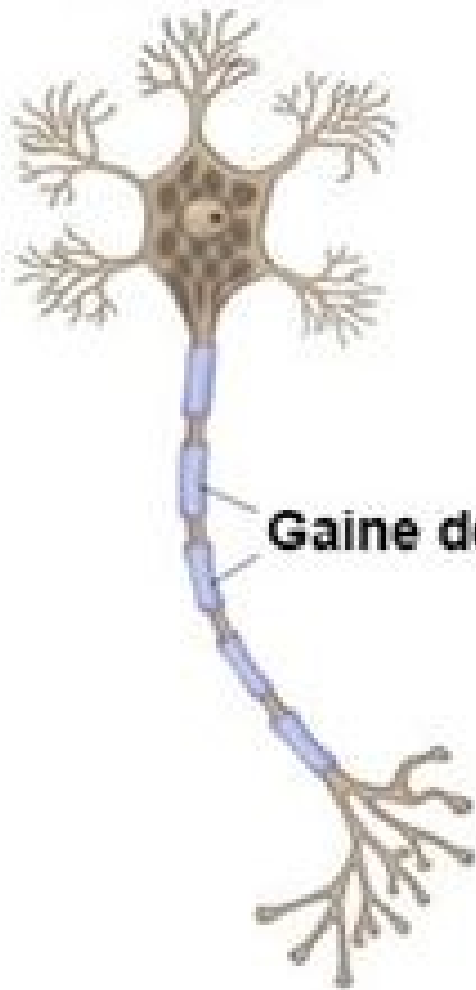
Accident hémorragique



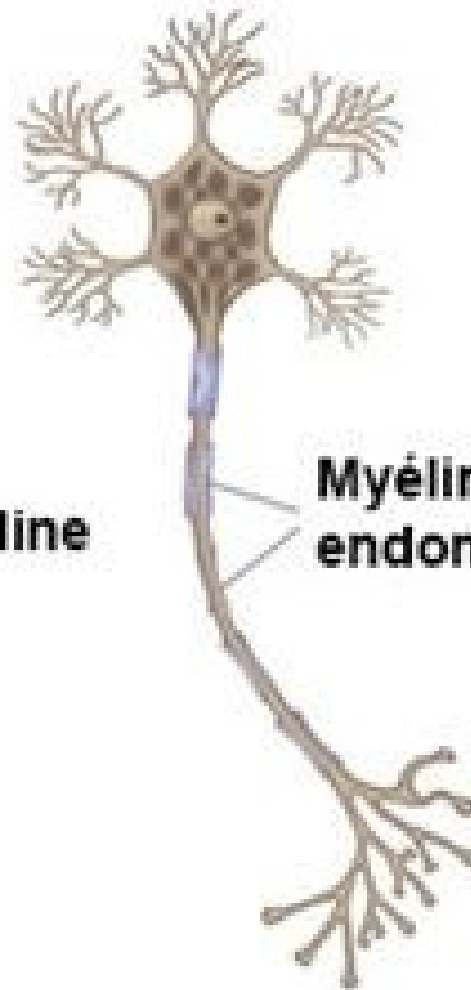
Rupture des vaisseaux, fuites de sang

Sclérose en plaques

Normal



Gaine de myéline



Myéline endommagée

